

Clinical Case Study: Scar MD Silicone Gel and Spray  
9.25.2014

## Scar MD Silicone Gel and Silicone Spray Clinical Case Study

### Prophylactic Use

Silicone Gel on breast augmentation scars, Silicone Spray on  
hysterectomy/tummy tuck scar.

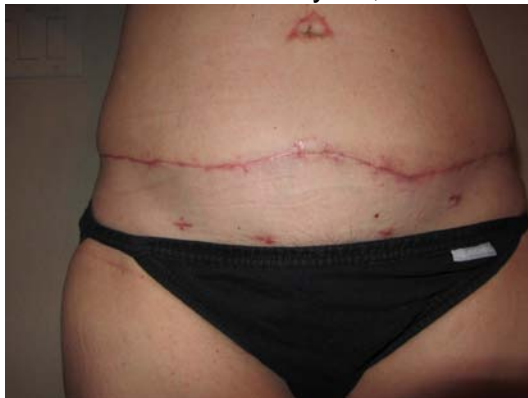Patient: Sherry

Procedure: Hysterectomy + Tummy Tuck

Product: Scar MD Medical Grade Silicone Spray

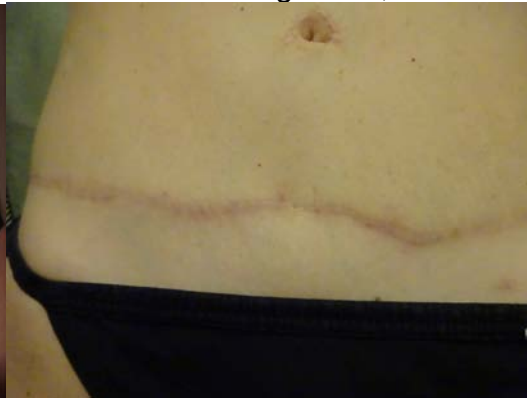Application: Two times per day, morning and night

Before: January 24, 2014



Scar red, slightly raised

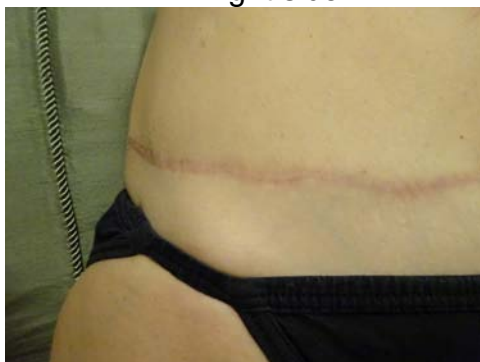After: August 24, 2014



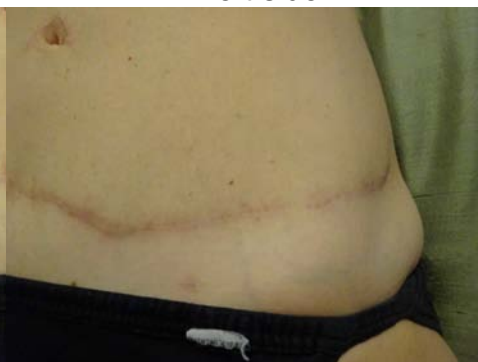Scar flat, even, very slight color,  
smooth to the touch

Post 7 months of treatment  
August 24, 2014

Right side

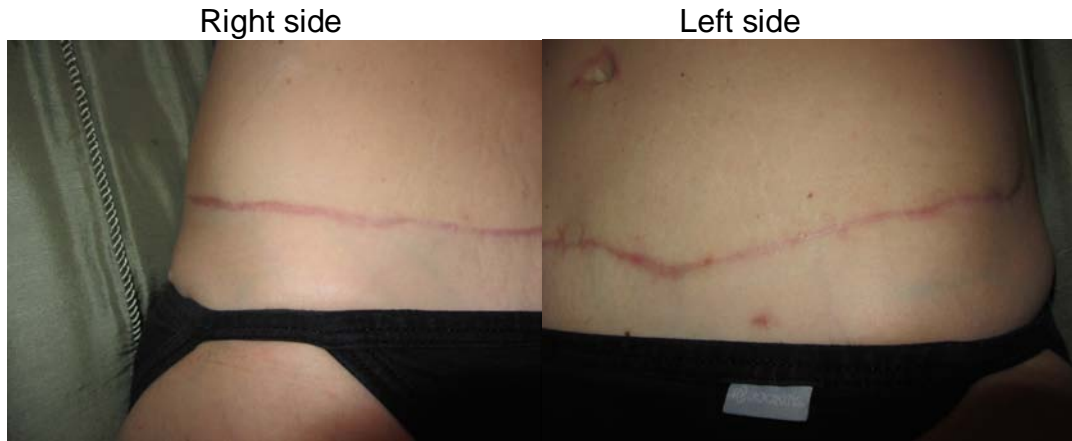


Left side

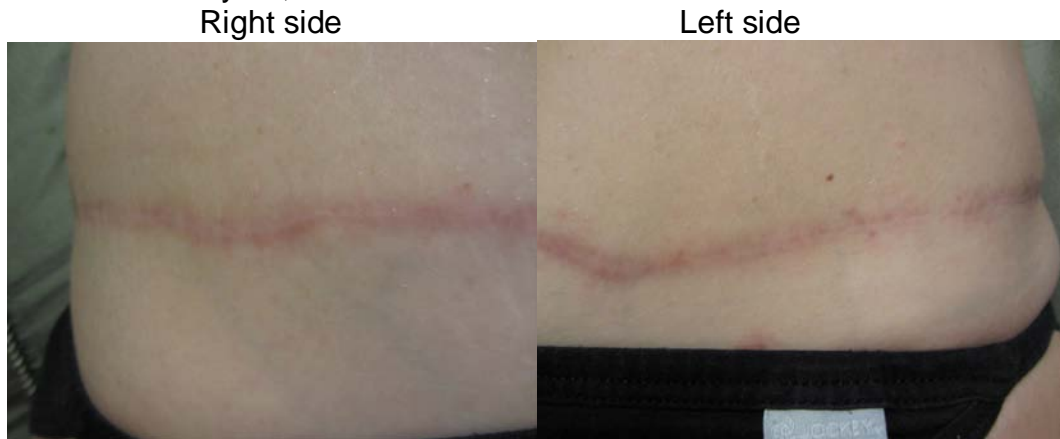


Clinical Case Study: Scar MD Silicone Gel and Spray  
9.25.2014

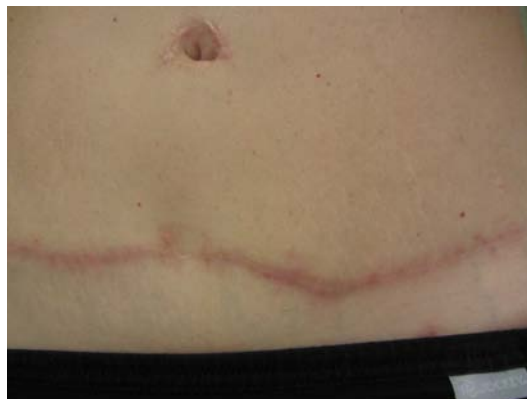At 3 months: April 25, 2014



At month 6: July 11, 2014.



At 6 months: July 11, 2014  
Center



Clinical Case Study: Scar MD Silicone Gel and Spray  
9.25.2014

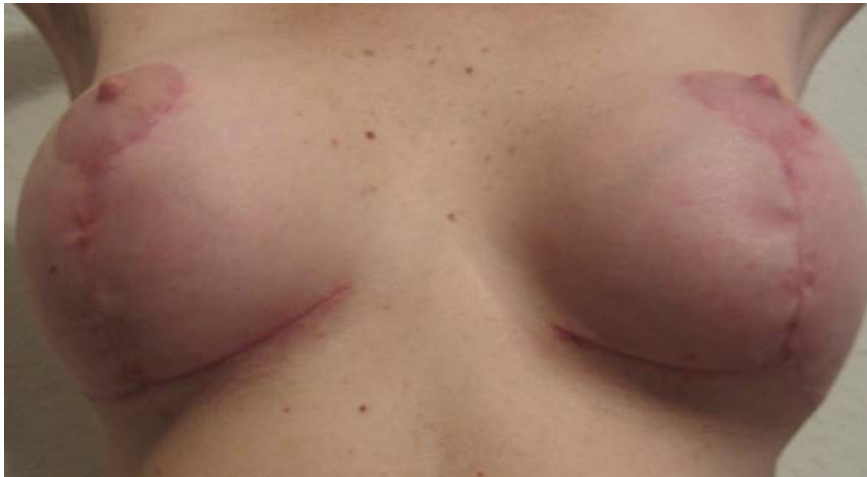Patient: Sherry

Procedure: Breast Augmentation scars

Product: Scar MD Silicone Gel

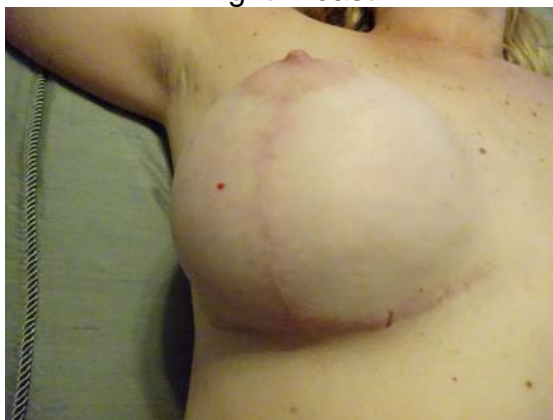Application: Two times per day, morning and night

Before: January 21, 2014 – X days post surgery.

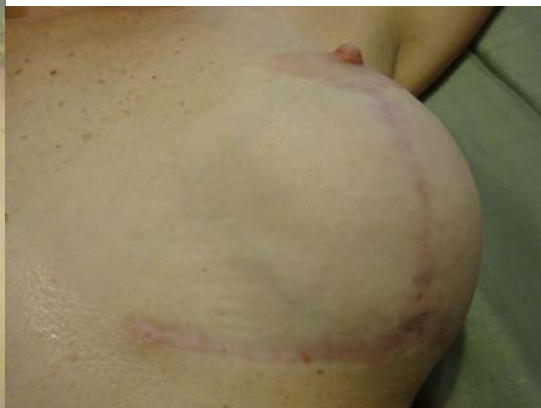

After: 7 months treatment: August 24, 2014

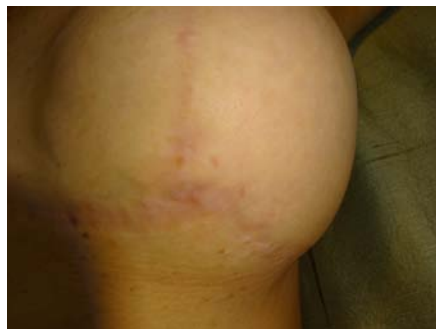Right Breast



Left Breast



Left Breast : under

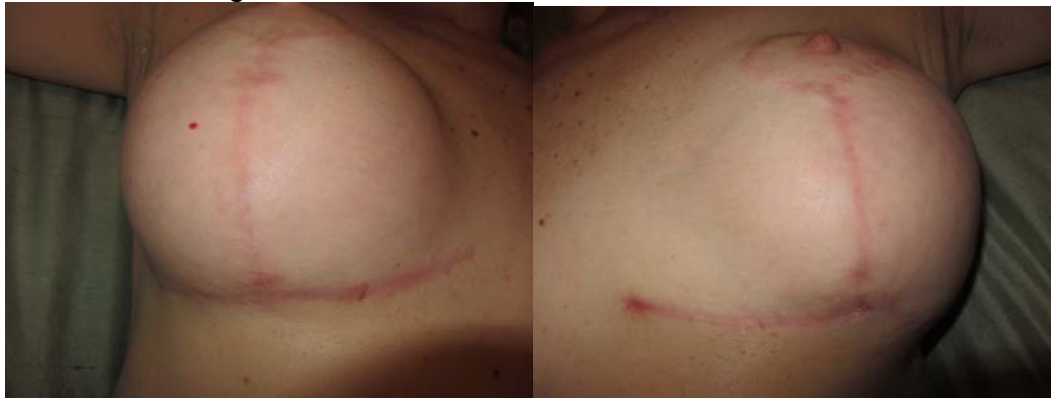

Clinical Case Study: Scar MD Silicone Gel and Spray  
9.25.2014

At 3 months: April 25, 2014

Right Breast

Left Breast



At 6 months

Right Breast

Left Breast

